

Rochester Institute of Technology

## RIT Digital Institutional Repository

---

Theses

---

8-2-2002

### The Function of canines in saber-tooth tigers

Colleen Hogan

Follow this and additional works at: <https://repository.rit.edu/theses>

---

#### Recommended Citation

Hogan, Colleen, "The Function of canines in saber-tooth tigers" (2002). Thesis. Rochester Institute of Technology. Accessed from

This Thesis is brought to you for free and open access by the RIT Libraries. For more information, please contact [repository@rit.edu](mailto:repository@rit.edu).

ROCHESTER INSTITUTE OF TECHNOLOGY

A Thesis Submitted to the Faculty of  
The College of Imaging Arts and Sciences  
In Candidacy for the Degree of  
MASTER OF FINE ARTS

The Function of Canines in Saber-Tooth Tigers

By  
Colleen J Hogan

August 2, 2002

# Signature Page

## Approvals

Chief Advisor James Perkins

(Signature) \_\_\_\_\_

Date: \_\_\_\_\_

8/13/02

Associate Advisor Frank Mendel

(Signature) \_\_\_\_\_

Date: \_\_\_\_\_

8/6/02

Associate Advisor Glen Hintz

(Signature) \_\_\_\_\_

Date: \_\_\_\_\_

8/6/02

Department  
Chairperson Thomas R. Lightfoot

(Signature) \_\_\_\_\_

Date: \_\_\_\_\_

8/13/02

I, \_\_\_\_\_, hereby grant permission to the Wallace Memorial Library of RIT to reproduce my thesis in whole or in part. Any reproductions will not be for commercial use or print.

Date: 8-13-02

## Acknowledgements

I would like to thank all those responsible for the success of this thesis, in particular:

My husband James; my family; my committee members: Glen Hintz, Frank Mendel, and Jim Perkins; and The Buffalo Zoological Gardens for the use of specimens.

A special thank you to John Nyquist – without your support and guidance this thesis would not have been possible.



# Contents

Acknowledgements iii

Introduction 1

Main Section:

Research Goals: Background Research 3

Research Goals: Results 5

Research Goals: Discussion 7

Research Goals: Conclusion 9

Illustrative Goals: Illustrating Bone and Muscle 10

Illustrative Goals: Illustrating the Hypotheses 13

Illustrative Goals: Output and Presentation 16

Illustrative Goals: Conclusions 17

List of Illustrations 18

Bibliography 19

## Introduction

The goal of my thesis is to illustrate how saber-tooth tigers used their enlarged canines to kill prey. I plan to illustrate several different hypotheses using traditional media and computer software. To accomplish this goal, I will dissect and illustrate heads of modern tigers and use them as models for interpreting saber-tooth tigers.

## Basic Premises

The basic premise of the thesis is that similar form, particularly among closely related organisms, usually means similar function. The extinct saber-tooth cat, *Smilodon fatalis* is in the same family as modern big cats, felidae. They were contemporaries in time and place. Therefore, it is conceivable that conclusions reached from dissecting *P. tigris* can be applied to *S. fatalis*.

Another premise is that movement of the head and jaw is restricted by anatomical configuration. In particular, muscles are only capable of stretching 30% of their total length, thus constraining movements to within specific parameters. The muscle configuration and amount of stretch directly affect the capabilities of eight protruding inches of canine teeth.

How were these large teeth were used to kill prey? Because of their length, there would have to be modifications of the skull bones and muscles that control movements of jaw. These anatomical changes occurred in tandem. The resulting configurations determine the maximum gape of the mouth, the power available to open and close the jaw, and ultimately how these animals killed their prey.

## Goals and Objectives

The first objective was to search the large literature on these extinct cats. Many hypotheses were expressed about how saber-tooth cats killed prey. However, few illustrations accompanied any of these theories. Without visual aids, readers of these theories could easily become confused.

Therefore, my illustrative goal was to create illustrations, geared to a scientific audience, to demonstrate two of the more common hypotheses about how *S. fatalis*, as a representative of saber-tooth cats, used their enlarged canines to kill prey.

The second objective was to understand the muscles of mastication of modern tigers, a close relative of roughly the same overall size as *S. fatalis*. Heads of two tigers were dissected to learn this anatomy. Bone scars, places where muscle attaches to bone, were of particular interest because these are the only indications on *S. fatalis* as to where the muscles were located.

My research goal was to determine the function of saber-like canines of the recently extinct cat, *S. fatalis*. The basic means of making this determination was by comparing the head anatomy of *S. fatalis* to that of modern tigers, *P. tigris*.

## Research Goals: Background Research

### Literature Review

The term 'saber-tooth tigers' encompasses a large number of species. One, *S. fatalis*, is represented by over a thousand individuals from La Brea asphalt pits in Los Angeles and is by far the best known of the saber-tooths.

The research began by reading much of a large amount of literature on *S. fatalis*. The majority of articles were written by a small group of people. An individual would discuss a new and improved idea pertaining to an existing theory and within a year, several other authors would either rebut or agree. Although many hypotheses have been proposed, the debate seems to focus on two: stabbing and slashing. Two authors hypotheses that represent these different schools of thought were selected to illustrate. Gonyea's stabbing hypothesis and Emerson and Radinsky's slashing hypothesis were illustrated because they provided extremely detailed descriptions of how they believe *S. fatalis* killed prey.

### Dissections

Supplemental to the reading, masticatory muscles of two modern tigers (*Panthera tigris*) were dissected. These muscles - digastricus, masseter, medial pterygoid, and temporalis - control jaw movements and consequently, all attach on the skull.

The head of a female tiger was sawn in half along the sagittal plane and then detached from the body. This made it possible to view muscle attachments located

on both the exterior and interior of the skull. However, because the specimen was embalmed, the jaw could not be pried open.

The head of a male tiger was dissected, but left intact and used as a reference. Muscle proportions of the female were confirmed on the male. These proportions were then superimposed onto the skull of *S. fatalis* to create accurate representations of muscles.

In addition to muscles, it is imperative to know bony structures associated with the overlaying muscles. Muscles insert into bone and create scars. Bone scars are areas left from where a muscle used to attach to the bone. When illustrating the skull and mandible, very close attention was paid to every bone scar.

## Research Goals: Results

### Muscle

Digastricus is the only masticatory muscle used primarily for jaw opening. It originates on the jugular process on the skull, and inserts on the interior border of the mandible (figure 3).

Masseter is a jaw closing muscle. It originates primarily on the zygomatic arch of the skull and inserts onto the lateral surface of the coronoid process of the mandible (figure 4). This is a deceptively complex muscle due to fascial covering. The thick fibrous fascia covering most of the surface of masseter suggests that the underlying muscle fibers also parallel the fascia fibers. That is incorrect, only the visible superficial fibers run in that direction and ultimately insert into the fascia. The underlying muscle fibers begin a trend that ends with the deepest fibers running medially to laterally.

Medial pterygoid, another jaw closer, attaches on the skull in the pterygopalatine fossa. Insertion of medial pterygoid is on the medial side on the mandible, inferior to the mandibular foramen (figure 5).

The deep head of temporalis is also a jaw closer. Its origin is on the skull - the floor of the temporal fossa extending up onto the nuchal and sagittal crests. The insertion is on the coronoid process of the mandible (figure 6).

### Bone

Many differences, subtle and obvious, exist between the bones of *S. fatalis* and *P. tigris*. The most obvious bony difference is the size of the canines. About



three times as much canine tooth protrudes from the skull of *S. fatalis* as from *P. tigris*.

The height of the coronoid process is another striking difference. Greatly reduced in *S. fatalis*, it's speculated this reduction would result in an increased amount of stretch by the deep head of temporalis, allowing a wider gape.

The zygomatic arch, like the coronoid process, is also reduced in *S. fatalis*. The change impacts masseter by decreasing the surface area of its origin on the skull of *S. fatalis*.

Although not as obvious, the jugular process is also quite different. *S. fatalis* has a much larger jugular process than *P. tigris*. This creates an expansive origin for digastricus, possibly resulting in a larger, more powerful jaw opening muscle.

## Research Goals: Discussion

The results of this thesis investigation were unexpected and unending. The beginning of the investigation yielded few surprises. As my knowledge of this topic expanded so did its complexity. Reading the research papers brought to light the fact that the same material has been regurgitated for decades. Scientists conduct studies employing new measuring techniques, in which results are quantified and conclusions drawn. Rarely do they question the “fundamentals”. Going back to the basics of dissecting a close relative of *S. fatalis* brought new information to the surface.

Based on muscle measurements and bone scars, it became obvious that the presumed size of masseter was grossly underestimated. The dissections revealed that masseter is larger, thicker, and comprised of more layers than previously thought. Temporalis is a large, powerful muscle that also has several layers, but without the complex origin and insertion of masseter. Because the size of the muscle was misrepresented, the placement was also imprecise. With the correct measurements applied to masseter on the *S. fatalis* skull, the balance of power shifts. Traditional thinking suggests that the power for mastication in carnivores comes primarily from temporalis, not masseter. This may not be the case in modern cats.

The other staple for hypotheses concerning gape is that temporalis controls how wide the jaw can open. This tenet is also being challenged. The research projects that dealt with the angle of gape based solely on temporalis must be re-tested using masseter as the primary restriction. This is also true for the research



that was conducted on power and ability to open and close the jaw based on temporalis.

The discovery of masseter's size, complexity, and potential power may be hazardous to existing hypotheses that revolve around temporalis as the sole determinant of gape and strength in the jaw. Although my intention was not to challenge others' research, I believe that this was a successful thesis: new ground was broken and many years of hard work and dedication must be put forth before this topic can be laid to rest.

## Research Goals: Conclusion

Although *S. fatalis* and *P. tigris* are different animals, their anatomical similarities allow probable conclusions to be reached. The differences in bony configuration between *S. fatalis* and *P. tigris* indicate differences in muscle. The reduced height of the coronoid process results in a longer temporalis muscle capable of greater stretch. This increased amount of stretch would enable *S. fatalis* to open its jaw wide enough to use the enlarged canines. Opening the jaw, against the resistance of jaw closers - temporalis and masseter, requires a strong jaw opener. The jugular process is much larger on *S. fatalis* than *P. tigris*, creating a bigger attachment site for digastricus. This increased surface area may translate into a larger, more powerful muscle. A powerful digastricus is essential in order to stretch temporalis and masseter the amount needed for clearance between the canines.

Combining the aforementioned anatomical changes allow *S. fatalis* to achieve a wide enough gape to successfully use its canines in a stabbing and or slashing manner.

## Illustrative Goals: Illustrating Bone and Muscle

Twelve illustrations were created to demonstrate the origin and insertion of each masticatory muscle for *S. fatalis* and *P. tigris*. First, lateral views of a *S. fatalis* skull were drawn with the jaw open (figure 1) and closed (figure 2). A lateral view of a *P. tigris* skull with the jaw closed was also created. These illustrations served as the bases for the ten remaining bone and muscle images.

Digastricus was the first muscle illustrated. Because digastricus is visible on both the medial and lateral surfaces, a portion of the mandible had to be recreated over the muscle to accurately depict the muscle's position. A shadow was added to reinforce the relative positions of the two structures (figures 3 & 9).

The next muscle of mastication drawn was masseter. This was a difficult muscle to illustrate due to its complexity and deceptive fascial covering. The thick fibrous fascia covering most of the surface of masseter suggests that the underlying muscle fibers also parallel the fascia fibers. That is incorrect, although anatomical drawings of big cats often depict it that way. *S. fatalis* was depicted with muscle fiber direction and *P. tigris* was illustrated with a thick facial covering over masseter (figures 4 & 10).

Medial pterygoid posed the most challenges. In order to view the origin of this muscle, a part of the zygomatic arch had to be removed. This was done visually since the actual skulls could not be sawed apart. This was achieved by cutting away a portion of the zygomatic arch - indicated by the cut ends depicting the inside of bone – and illustrating the pterygopalatine fossa in its place (figures 5 & 11).

A different technique was employed for the mandibular insertion of medial pterygoid. Conveying this information to the viewer required both the interior and exterior of the skull and mandible at the same time. The exact place where the

muscle inserts needs to be seen, however, this can become confusing. If the muscle appears vibrant and unobstructed the viewer will think it crosses in front of the mandible and inserts on the lateral side. A method called ghosting was used to solve this problem. The edges of the mandible are left at 100% opacity, while the opacity of and around the insertion point is 30% (figures 5 & 11). This gives the illusion that the bone is transparent so the muscle can be seen through it.

Temporalis was the last muscle to be illustrated. It is also a jaw closer with its origin on the skull and insertion on the coronoid process of the mandible. Showing the insertion again necessitated removal of the zygomatic arch (figures 6 & 12).

The two final muscle and bone images created were a compilation of the aforementioned muscles: digastricus, masseter, medial pterygoid, and temporalis. These two illustrations, one each for *S. fatalis* and *P. tigris*, put into perspective the relative size, interactivity, and subsequent actions of the muscles of mastication.

The same approaches were used in creating six illustrations of *P. tigris*. The initial base illustration of skull and mandible was created directly from its respective skull and mandible. Even though this thesis is about *S. fatalis*, the inclusion of *P. tigris* was essential. Every muscle depicted on *S. fatalis* was directly referenced from *P. tigris*. The only way to completely appreciate the differences between the two animals is to present them side-by-side.

The initial image depicts *S. fatalis* with the jaw positioned in a 90° gape (figure 1). In the subsequent images the jaw is closed (figures 2-7). This adjustment was due to the inability to pry the deceased tiger's mouth open. This deceased tiger was the principal animal used in the modeling. It was important that the representation of muscle on *S. fatalis* was as accurate as possible, thus mimicking its closed position.

All bone and muscle illustrations were created solely in Adobe® Photoshop®. The illustrations comprised only of bone (figures 2 & 8) were used as base art for the muscle illustrations. The process of creating these illustrations followed the same steps of a traditional painting or airbrushed image. They began with an outline of the form, followed by large, vague areas of highlight and shadow. Refined details emerged with time and meticulous, methodical effort. The majority of the images were created with the airbrush tool. To increase the positioning possibilities, the skull and the mandible were kept on separate layers within Photoshop®. This technique permitted the jaw to be in any position, from closed to disarticulated. Using this method, the jaw of *S. fatalis* was closed for the remaining muscle images. When creating the two illustrations depicting the hypotheses, different methods were employed.



## Illustrative Goals: Illustrating the Hypotheses

The two hypotheses selected were Gonyea's stabbing hypothesis and Emerson and Radinsky's slashing hypothesis. Both hypotheses were very specific as to the method of attack and area of insertion of the canines. Each hypothesis has five important components that must be accurate to fairly represent each author's opinion: method of attack, position of *S. fatalis* relative to prey, position of prey, size of prey, and the anatomy relevant to the killing method employed by *S. fatalis*.

Gonyea's stabbing hypothesis states, "...they (*S. fatalis*) probably killed their prey by grasping and controlling the victim with the forelimbs and while the canines were used exclusively for killing by a stab to the nape of the neck or posterior skull region" (Gonyea 1976).

He describes the position of predator and prey stating, "Large prey are rarely knocked over by the impact of the predator's body; instead, during the pounce, the hind feet of the felid usually do not leave the ground. The prey is seized and the predator pulls the prey toward itself. In this manner, as the victim is pulled down, the predator is able to maintain contact with the prey, and in doing so controls the victim's movements (Gonyea 1976)." He also mentions the potential danger to the embedded canines from struggling prey and the importance of being in the correct position to deliver a lethal stab.

Gonyea claims the size of prey would be large, stating most large carnivores kill prey the same size or larger than themselves. Even though horses were not specifically mentioned, they are a suitable choice of prey. Their average size is appropriate for Gonyea's hypothesis and they were contemporaries of *S. fatalis*.

The hypothesis was drawn in pencil then scanned into Photoshop® for colorization. The texture, detail, and style of the pencil were desired aspects, however, the grayscale component was not. The image was too different from the vibrant full-color Photoshop® images. To integrate the image into the body of work through colorization, yet retain the desired qualities that separate it from the other Photoshop® images, the color was added in overlay and multiply mode.

Rendering Gonyea's hypothesis 2-dimensionally as a single image (figure 15), it was difficult to portray the actual stab that would produce lethal results. Instead, utilizing the word 'stab', the viewer must finish the sequence of events in his mind. *S. fatalis* is seconds away from plunging canines into the neck of the horse.

Interpreting Gonyea's statement about position illustratively, *S. fatalis* was positioned on hind limbs grasping and controlling the prey with the forelimbs (figure 15). This helped prevent injury from flailing limbs of the prey as well as injury to the canines. The position also allows the viewers of this illustration to witness the entire act.

The anatomy of the horse's neck was researched and the cervical vertebrae were illustrated in their correct position in the horse's neck. The spinal cord, encapsulated by the bones, is the target. Because this area is extremely important, the viewer needs to see it without having to search for it. The vertebrae were created using opaque, dark colors to help separate them from the body of the horse, indicating they are internal structures, and to bring attention to the area.

Emerson and Radinsky, on the other hand, feel that the canines were too fragile to encounter bone without breaking. Therefore, the cat must attack an area that would have a lethal effect without penetrating bone. Emerson and Radinsky believed *S. fatalis* employed a slashing technique to kill prey. Their slashing hypothesis states, "...they [the canines] were used against a relatively convex body surfaces where there was little chance of hitting bone and where a superficial

wound could be effective.” They concluded that the ventral neck or throat was the likely target (Emerson and Radinsky 1980). There are many vulnerable structures in the neck: carotid arteries, jugular veins, and the trachea. All of these structures can be reached with a shallow slash without nearing the cervical vertebrae.

Emerson and Radinsky were not as specific as Gonyea in describing the position of *S. fatalis* in relation to prey. They did mention, however, the need for *S. fatalis* to control the prey. This is very important for the mode of attack because immobilization aids accuracy. To immobilize the throat, the cat would have to keep the prey’s head and shoulders pinned to the ground.

Emerson and Radinsky believe that the prey size was medium to large. In order to maintain continuity and avoid confusion, the same prey species was used in both illustrations.

The important structures in the ventral neck: carotid arteries, jugular veins, and trachea, were handled in the same way as with the stabbing hypothesis. The windpipe was a bright, opaque pink and the carotid arteries were a deep red.

This illustration was also created in pencil and scanned into Adobe® Photoshop® (figure 14). As with the stabbing hypothesis, one illustration was used to convey the information. The obvious difference is the intended target; this time it’s the ventral neck or throat.

In the illustration, *S. fatalis* is using its forelimbs to control the horse. The left arm is holding the shoulder down while the right is pulling the horse’s head around to expose the target area.

This grayscale, pencil illustration was also scanned into Photoshop® and colorized in the same manner as described above for the stabbing hypothesis.



## Illustrative Goals: Output and Presentation

The images created were intended for print and/or museum exhibits. They were created with a resolution of 300 dpi. This level of resolution will ensure the ability to print in a wide size range, journal to wall. Output for all the illustrations was the same, printed as Adobe® Illustrator® eps files, 150 dpi on glossy photo paper.

The sizes varied among the four pieces. The first piece featuring *Smilodon fatalis* – Jaw 90°, was 24 x 24 inches. The stabbing hypothesis was 18 x 24 inches and the slashing hypothesis was 24 x 18 inches. The last piece is comprised of three equal sized pieces, 24 x 20 inches, set flush against each other to create one image.

All illustrations were dry mounted on foam board. The thesis presentation was hung on two 4 x 8 foot panels arranged side by side to give an overall area of 8 x 8 feet. The arrangement of images began with the 24 x 24 inch illustration. This piece serves as a steppingstone into the bulk of the artwork. The viewer is introduced to *S. fatalis* and given a brief description of the purpose of the thesis.

The next two pieces are the slashing and stabbing hypotheses. Beneath the three separate pieces is the six - foot long, twelve - image compilation of bone and muscle from *S. fatalis* and *P. tigris*. This piece was arranged from left to right in degrees of complexity - from just bone to all four masticatory muscles in one image. *S. fatalis* images were placed on top of *P. tigris*, separated by slightly different background colors (figures 16 & 17).

## Illustrative Goals: Conclusions

Prior to the illustrations created for this thesis, few images depicting muscle placement on *S. fatalis* existed. This is also true for illustrations of hypotheses of how *S. fatalis* killed prey. Of the images that did exist however, many were illustrated in a vague or inaccurate manner. In order to satisfy the goals and objectives of this thesis, the images created were highly detailed and as precise as possible. The anatomical accuracy and amount of detail included in every image is appropriate and necessary for the intended audience, the scientific community.

The principal illustrative goal of this thesis was to create illustrations that provide clarity and insight to existing hypotheses and ideas regarding *S. fatalis*. I believe this goal was satisfied with each one of the fifteen illustrations of *P. tigris* and *S. fatalis*.

## List of Illustrations

Figure 1	<i>Smilodon fatalis</i> - Jaw 90°
Figure 2	<i>Smilodon fatalis</i> - Jaw Closed
Figure 3	<i>Smilodon fatalis</i> -Digastricus
Figure 4	<i>Smilodon fatalis</i> - Masseter
Figure 5	<i>Smilodon fatalis</i> - Medial Pterygoid
Figure 6	<i>Smilodon fatalis</i> - Temporalis
Figure 7	<i>Smilodon fatalis</i> - All Four Muscles of Mastication
Figure 8	<i>Panthera tigris</i> - Jaw Closed
Figure 9	<i>Panthera tigris</i> - Digastricus
Figure 10	<i>Panthera tigris</i> - Masseter
Figure 11	<i>Panthera tigris</i> - Medial Pterygoid
Figure 12	<i>Panthera tigris</i> - Temporalis
Figure 13	<i>Panthera tigris</i> - All Four Muscles of Mastication
Figure 14	Slashing Hypothesis
Figure 15	Stabbing Hypothesis
Figure 16	Thesis Presentation – Left Wall
Figure 17	Thesis Presentation – Right Wall

## Selected Bibliography

- Akersten, William A. "Canine function in *Smilodon* (Mammalia; Felidae; Machairodontinae)." Natural History Museum of Los Angeles County Contributions in *Science* 356 (1985): 1-22.
- Antón, Mauricio, and Alan Turner. *The Big Cats and their Fossil Relatives: an Illustrated Guide to their Evolution and Natural History*. New York: Columbia University Press, 1997.
- Biknevicius, Audrone R. "Function discrimination in the masticatory apparatus of juvenile and adult cougars (*Puma concolor*) and hyenas (*Crocuta crocuta*)." *Canadian Journal of Zoology* 74 (1996): 1934-1942.
- Biknevicius, A. R., B. Van Valkenburgh, and J. Walker. "Incisor size and shape: implications for feeding behaviors in saber-toothed "cats"." *Journal of Vertebrate Paleontology* 16, no. 3 (1996): 510-521.
- Bohlin, Birger. "Food habit of the machaerodonts, with special regard to *Smilodon*." *The Linnean Society of London* 124 (1998): 369-386.
- Diamond, Jared M. "How great white sharks, sabre-toothed cats, and soldiers kill." *Nature* 322 (1986): 773-4.
- Emerson, Sharon B., and Leonard Radinsky. "Functional analysis of sabertooth cranial morphology." *Paleontology* 6, no. 3 (1980): 295-312.

- Gonyea, William J. "Behavioral implications of saber-toothed felid morphology." *Paleobiology* 2 (1976): 332-342.
- Greaves, Walter S. "Functional implications of mammalian jaw joint position." *forma et functio* 7 (1974): 363-376.
- Greaves, Walter S. "A functional analysis of carnassial biting." *Biological Journal of the Linnean Society* 20 (1983): 353-363.
- Greaves, Walter S. "The maximum average bite force for a given jaw length." *The Zoological Society of London* 214 (1988): 295-306.
- Iwago, Mitsuaki. *In the Lion's Den*. San Francisco: Chronicle Books, 1996.
- Kurten, Björn, and Lars Werdelin. "Relationships between North and South American *Smilodon*." *Journal of Vertebrate Paleontology* 10, no. 2 (1990): 158-169.
- Miller, George J. "New hypothesis to explain the method of food ingestion used by *Smilodon californicus* Bovard." *Tebiwa, J. Idaho State Univ. Mus.* 12 (1969): 9-19.
- Miller, George J. "Some new evidence in support of the stabbing hypothesis for *Smilodon californicus* Bovard." *Carnivore* III 2 (1980): 8-19.



Miller, George J. On the Jaw Mechanics of *Smilodon californicus* Bovard and some other Carnivores. El Centro, California: IVC Museum Society, 1984

Radinsky, Leonard B. "Evolution of skull shape in carnivores 1. Representative modern carnivores." *Biological Journal of the Linnean Society* 15 (1981): 369-388.

Radinsky, Leonard B. "Evolution of skull shape in carnivores 2. Additional modern carnivores." *Biological Journal of the Linnean Society* 16 (1981): 337-355.

Simpson, George Gaylord. "The function of saber-like canines in carnivorous mammals." *The American Museum of Natural History*, no. 1130 (1941): 1-12.

Smith, Maynard J. and R. J. G. Savage. "The mechanics of mammalian jaws." *The School of Science Review* (1958): 289-301.

Turner, Alan, Mauricio Antón, and Rosa Garcia-Perea. "Reconstructed facial appearance of the sabretoothed felid *Smilodon*." *The Linnean Society of London* 124 (1998): 369-386.

Van Valkenburgh, Blaire. "Incidence of tooth breakage among large, predatory mammals." *The American Naturalist* 131, no. 2 (1988): 291-302.

Figure 1

*Smilodon fatalis* – Jaw 90°

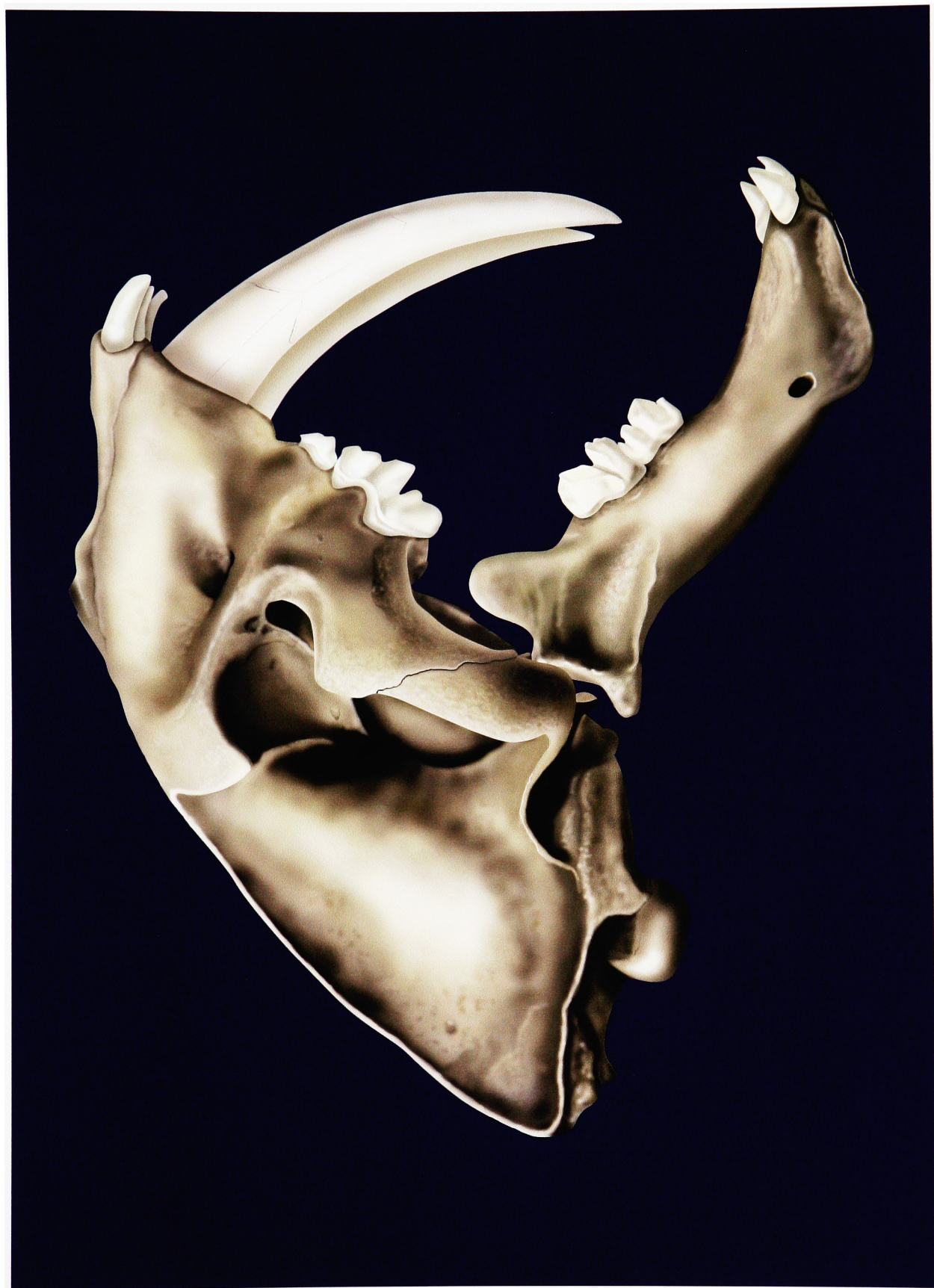



Figure 2

*Smilodon fatalis* – Jaw Closed



Figure 3

*Smilodon fatalis* – Digastricus



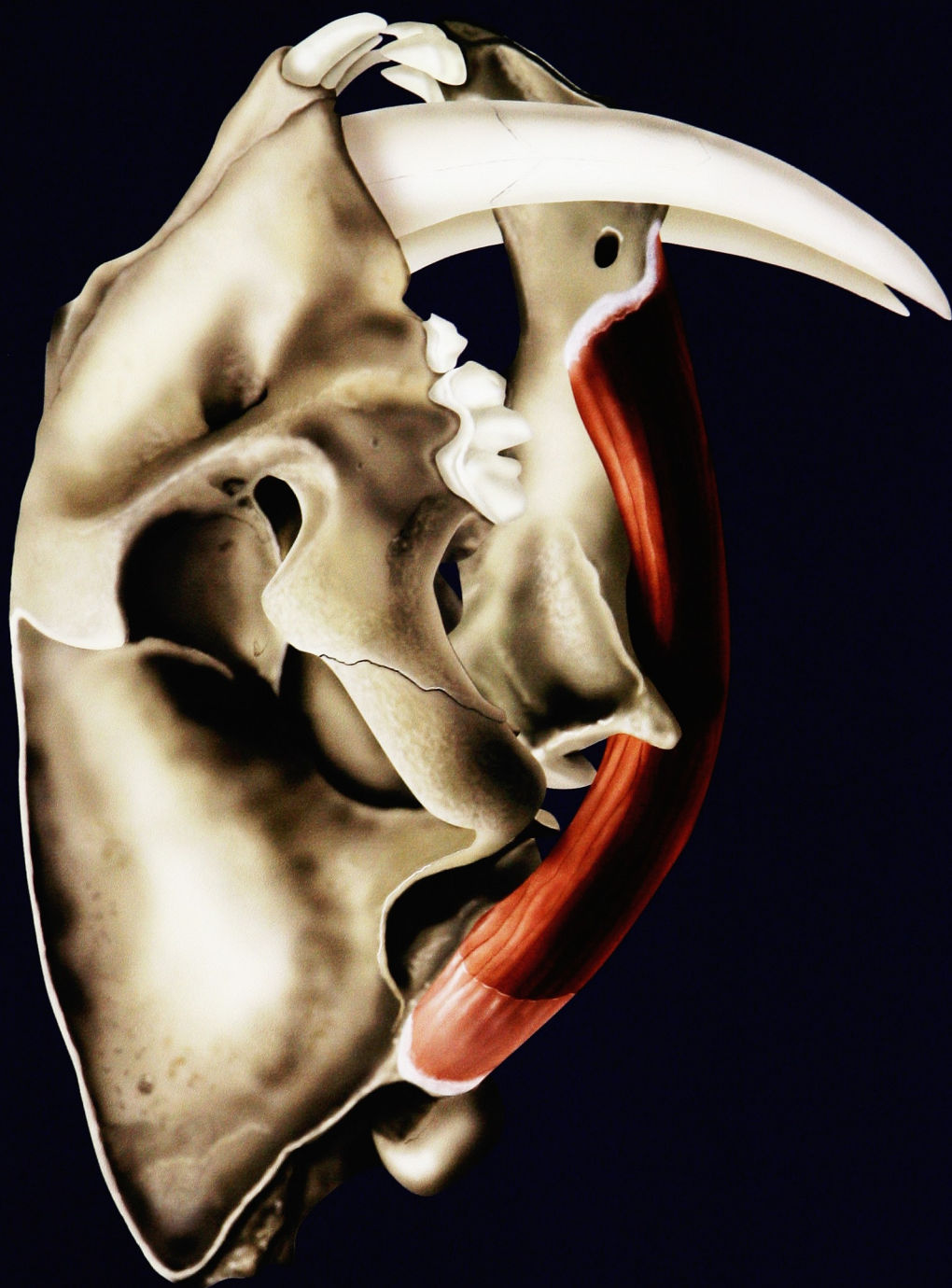

Figure 4

*Smilodon fatalis* – Masseter



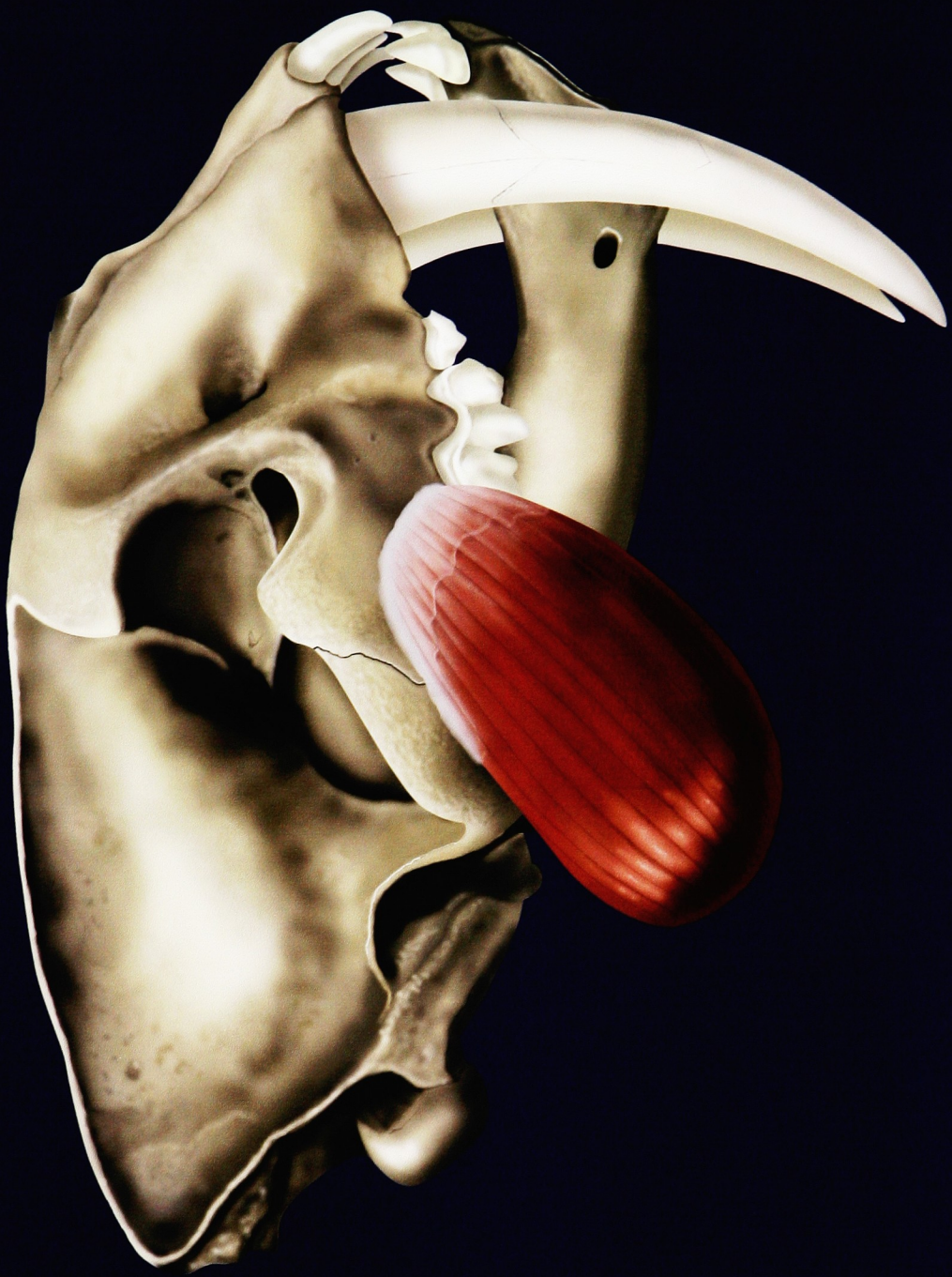

Figure 5

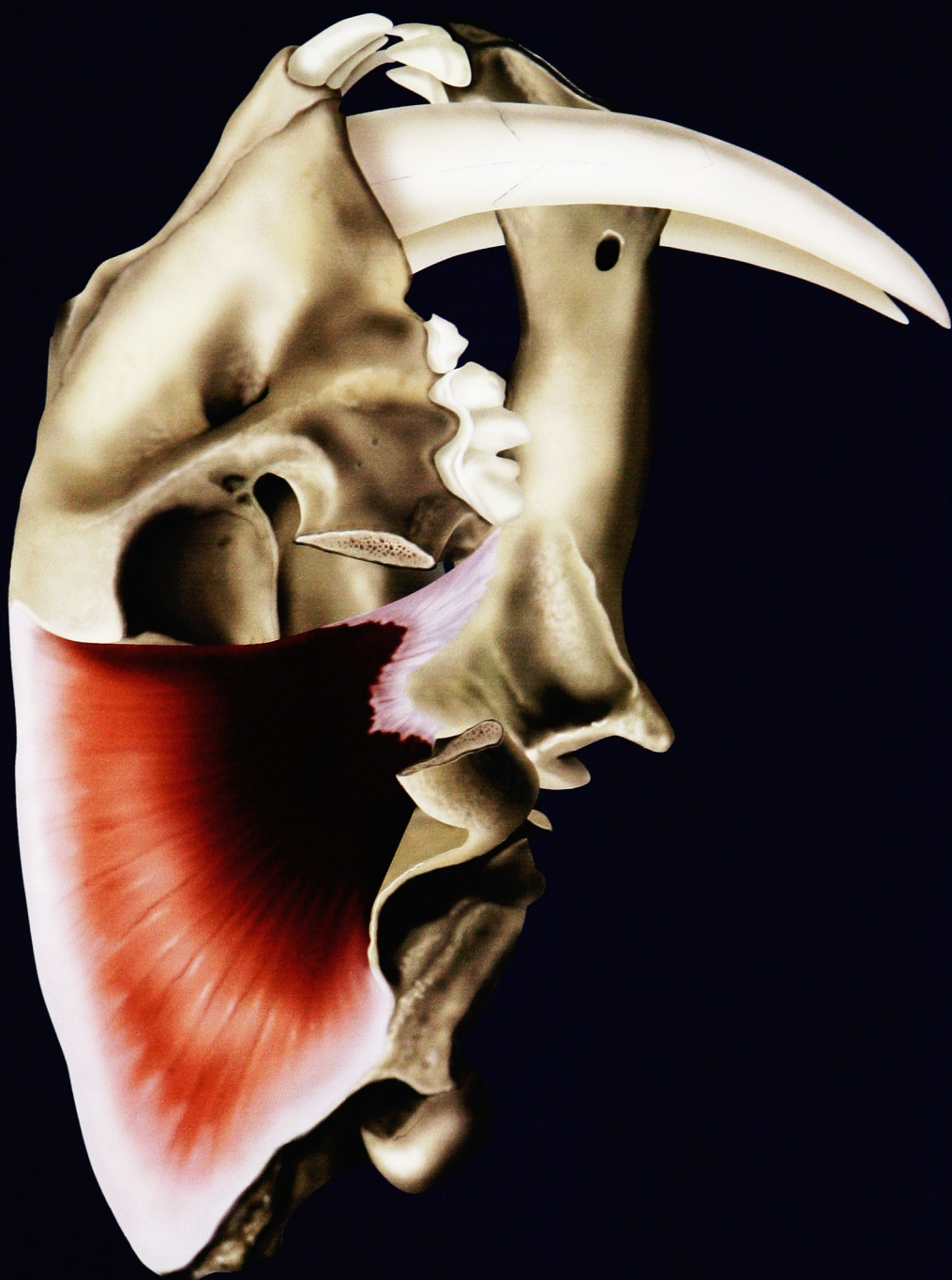
*Smilodon fatalis* – Medial Pterygoid



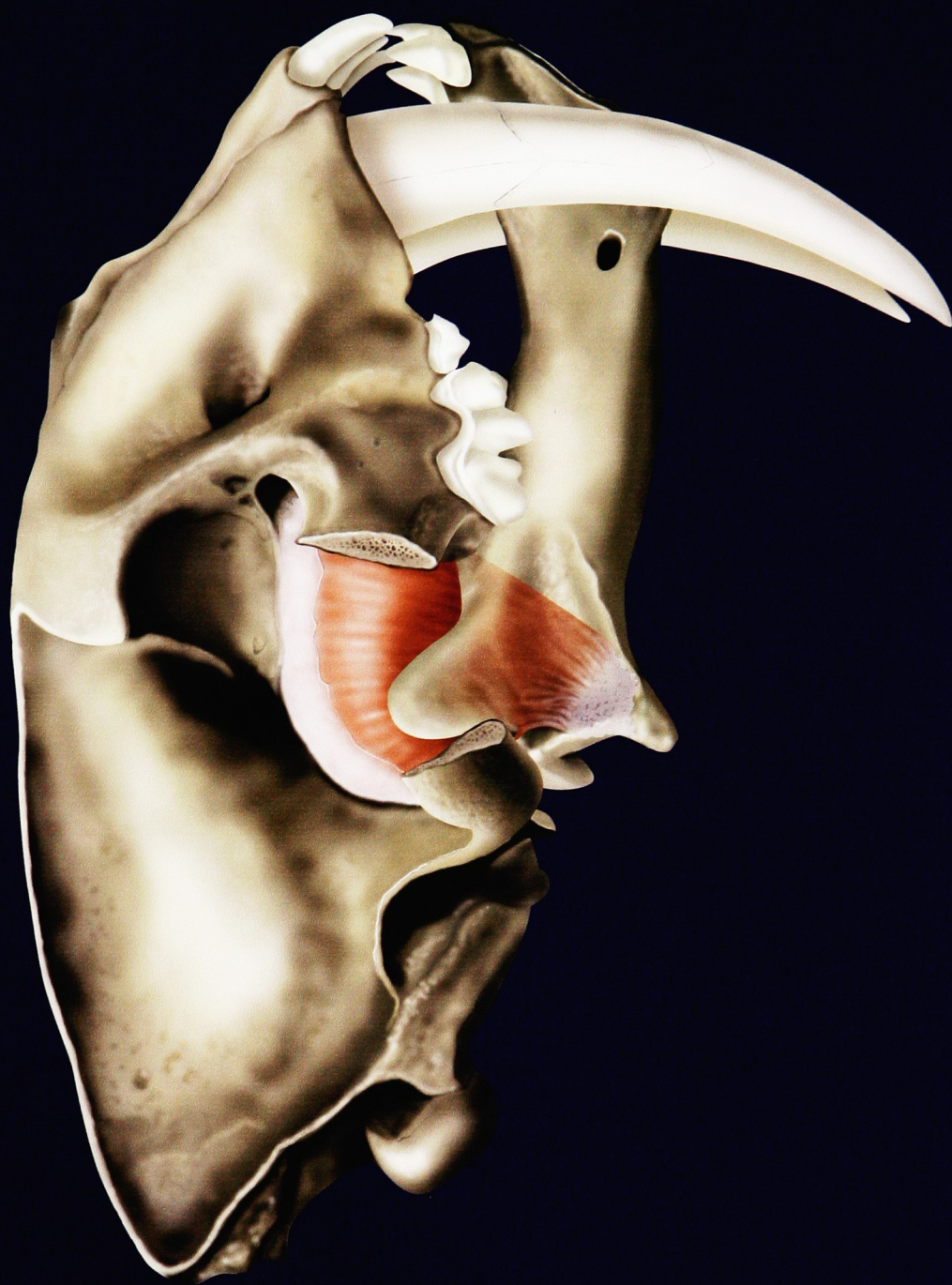



Figure 6  
*Smilodon fatalis* – Temporalis



## Figure 7

*Smilodon fatalis* – All Four Muscles of Mastication



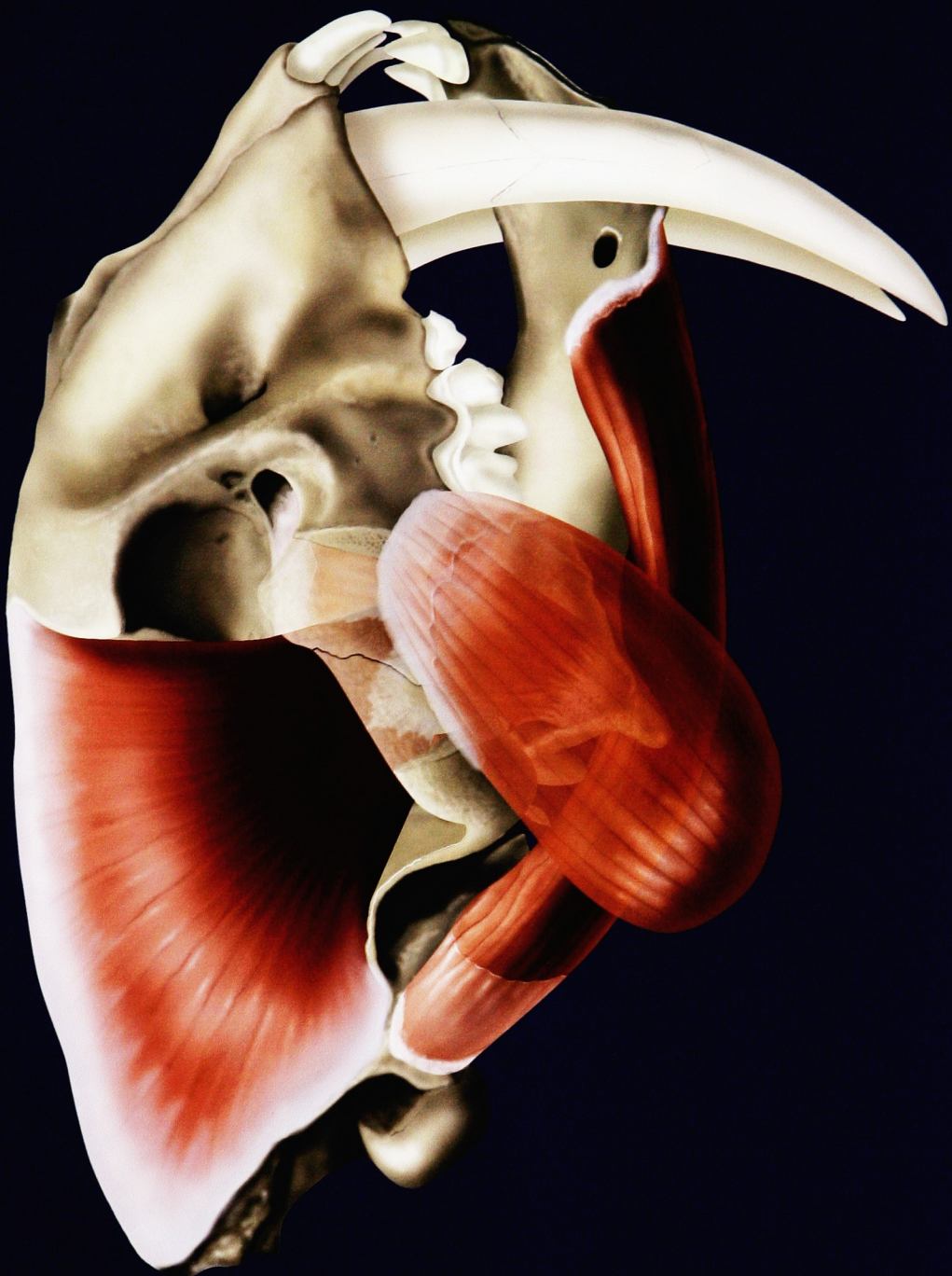

Figure 8

*Panthera tigris* – Jaw Closed



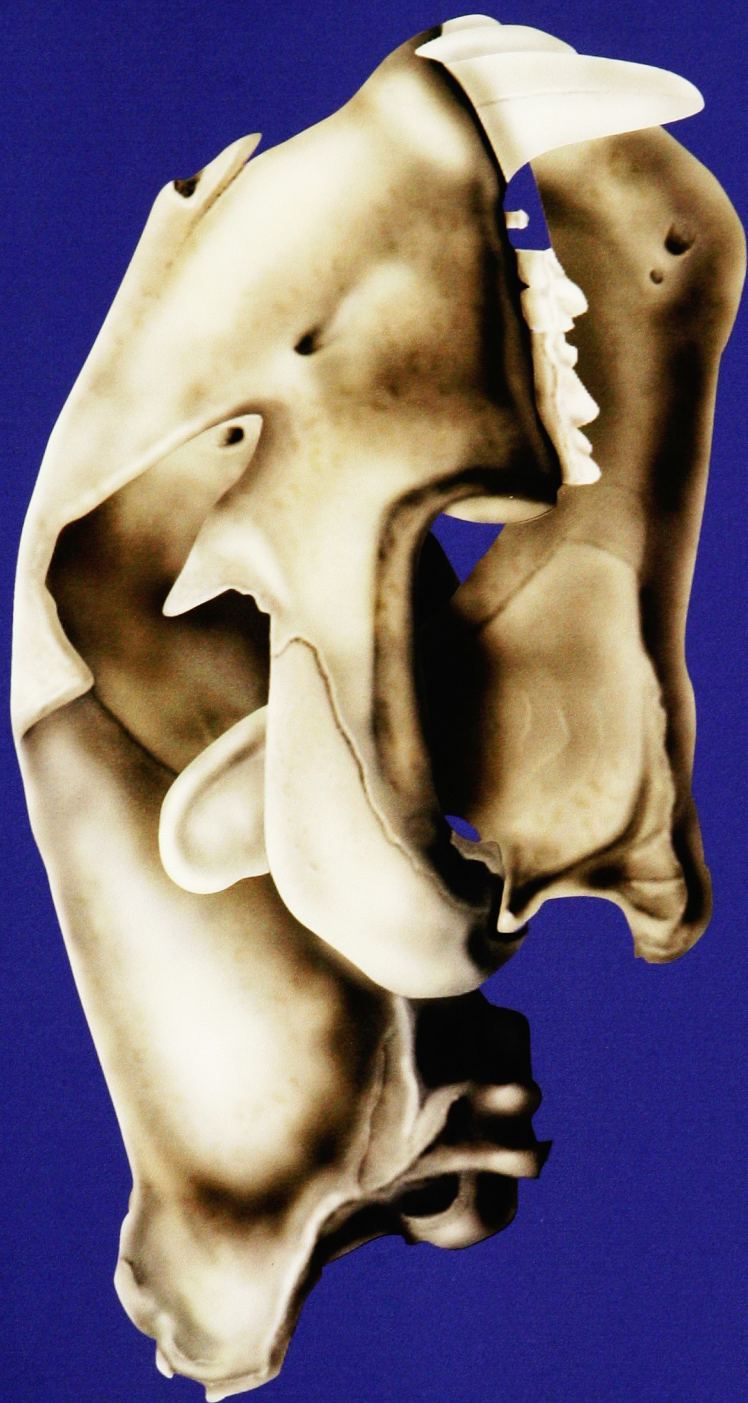

Figure 9

*Panthera tigris* – Digastricus



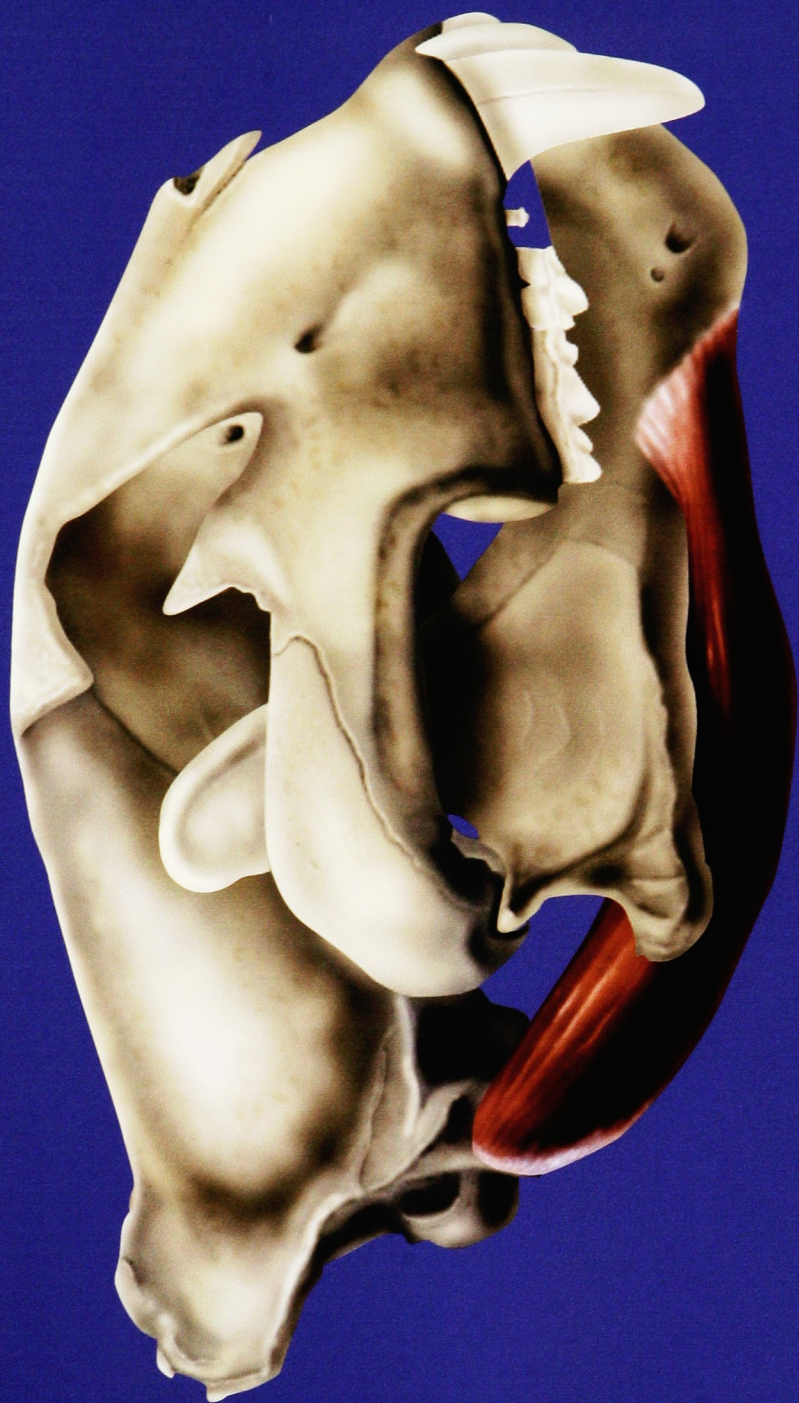


Figure 10

*Panthera tigris* – Masseter



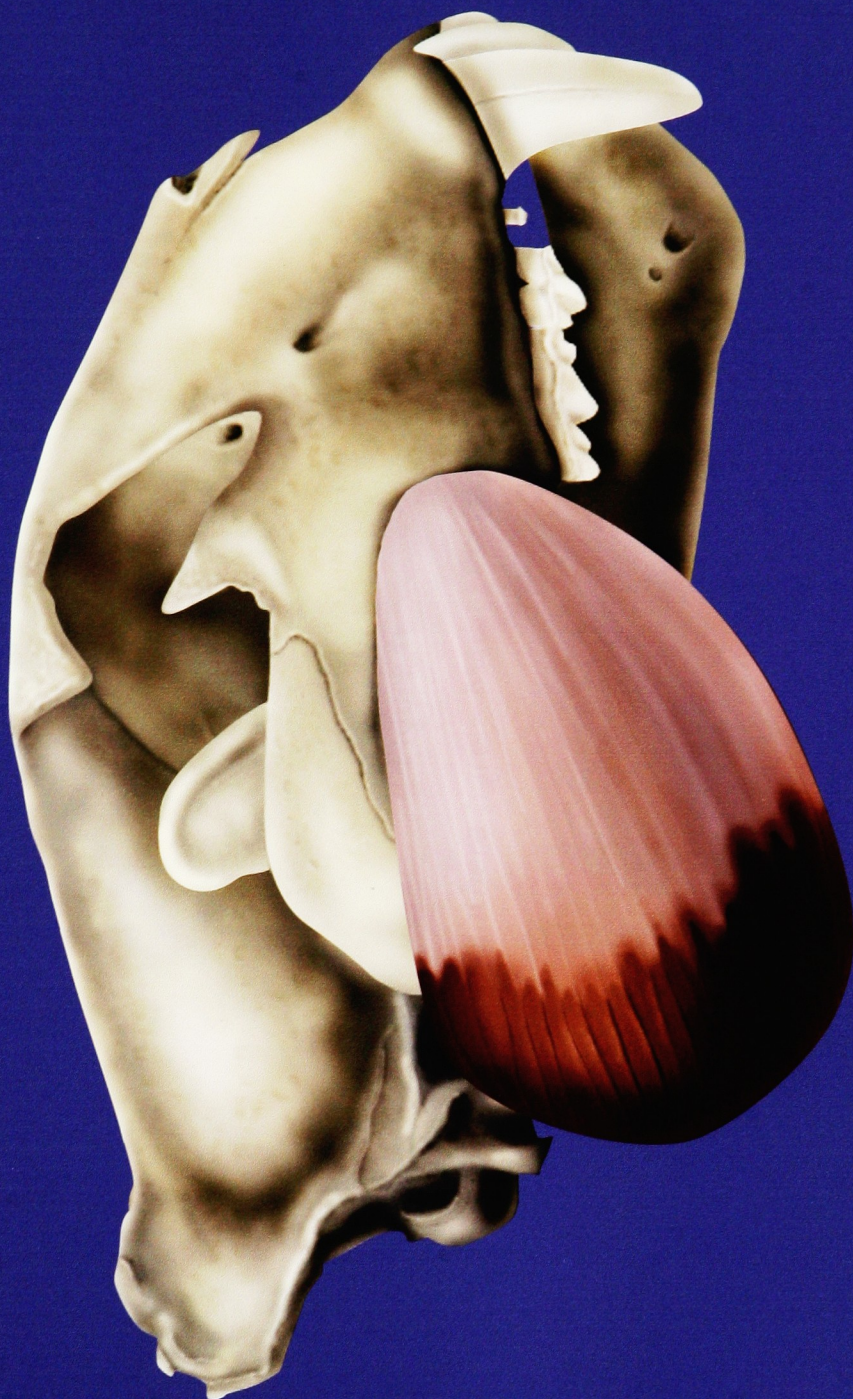

Figure 11

*Panthera tigris* – Medial Pterygoid



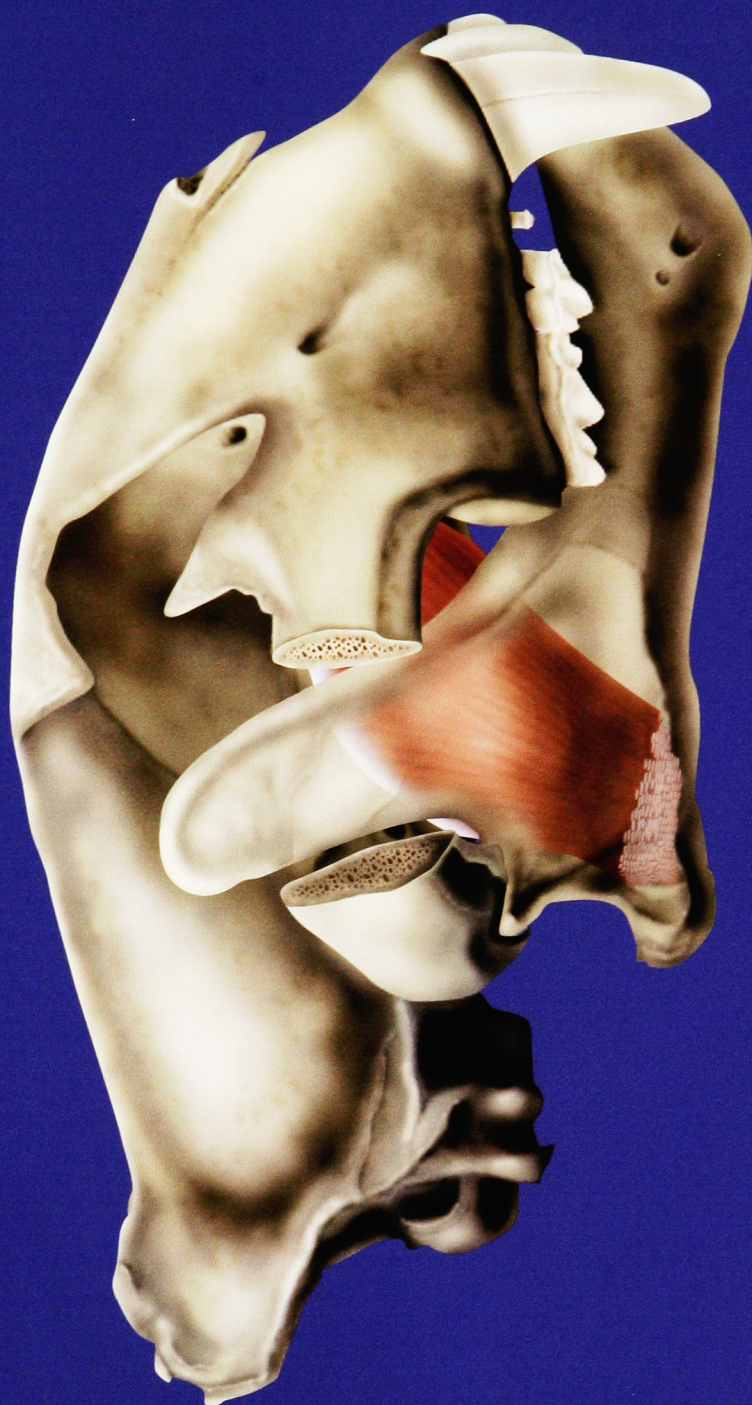


Figure 12

*Panthera tigris* – Temporalis



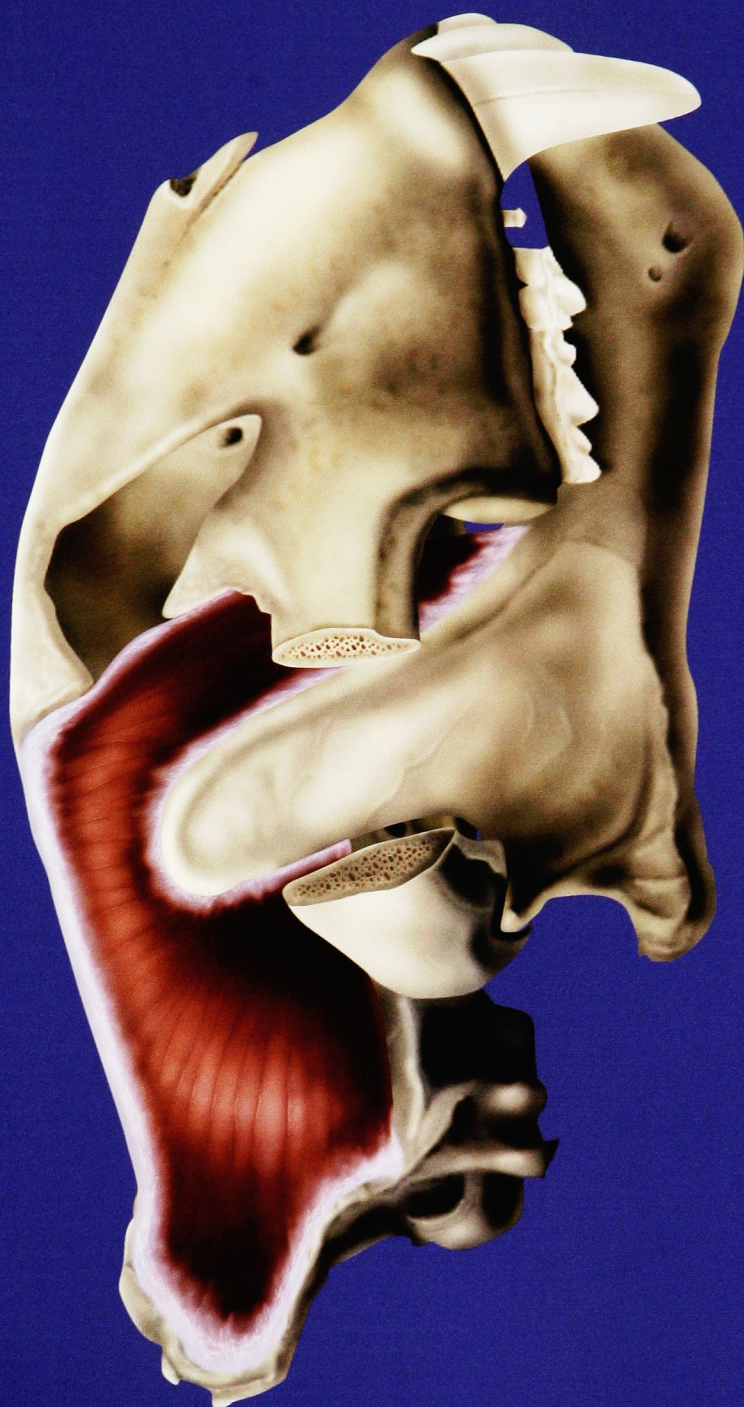

Figure 13

*Panthera tigris* – All Four Muscles of Mastication



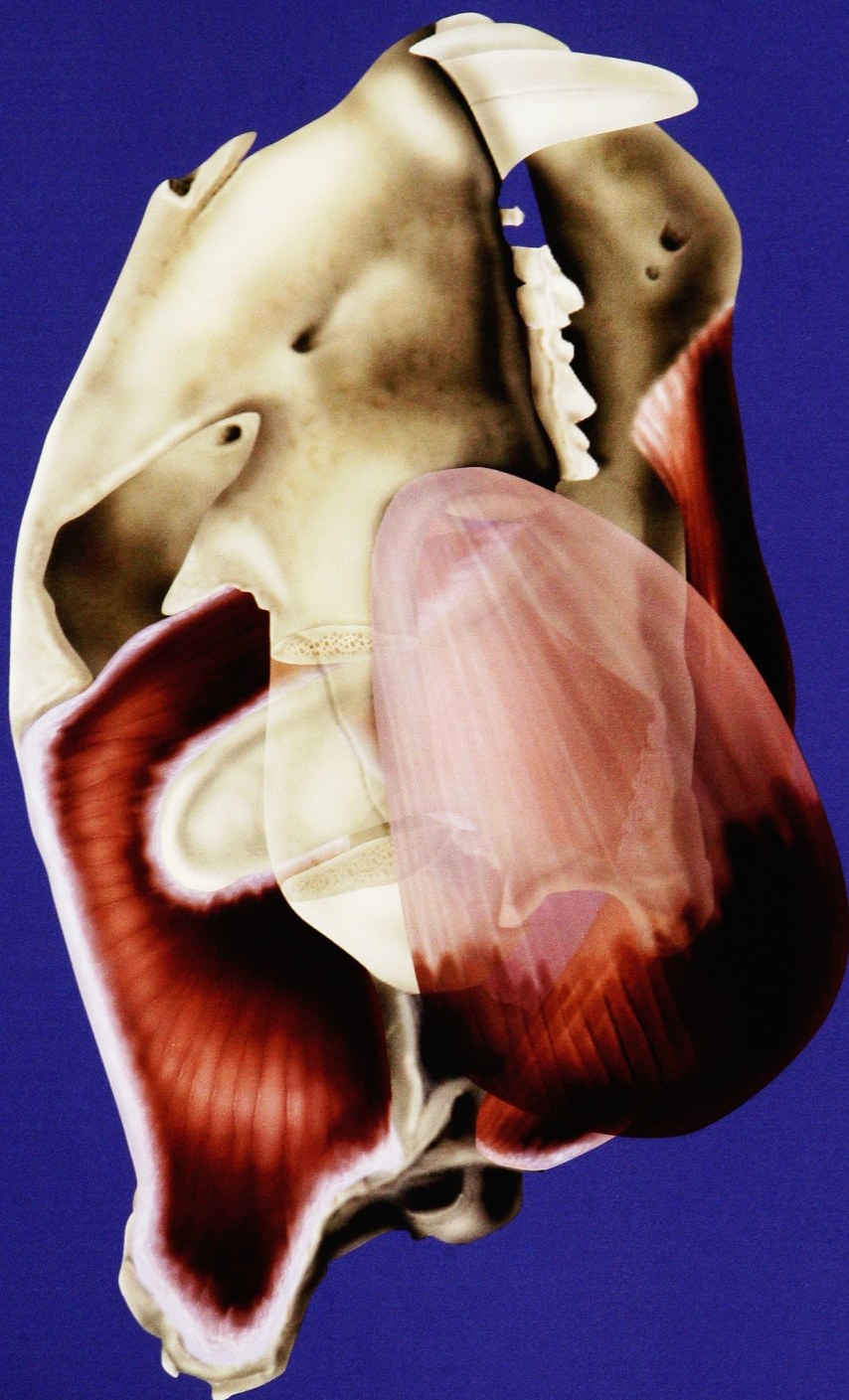


Figure 14  
Slashing Hypothesis





Figure 15  
Stabbing Hypothesis





Figure 16

Thesis Presentation – Left Wall

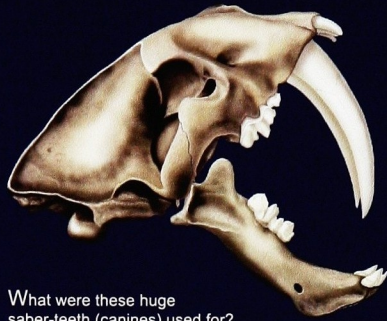
Figure 17

Thesis Presentation – Right Wall



# SMILODON FATALIS

"Saber-tooth cat"



What were these huge saber-teeth (canines) used for?

It seems obvious, but look at the above image - the mouth is open 90 degrees and there is minimal clearance between the teeth.

A critical question becomes, how wide could this animal open its mouth? Answers come from two sources: bone and muscle.

There are many differences between the skulls of saber-tooth cats and modern tigers. (illustrated below)




*Smilodon fatalis* roamed North and South America 3 million years ago, before becoming extinct about 10,000 years ago.

These differences directly affect the corresponding muscles of mastication. Muscles are the key to understanding the dynamics of jaw movement. (illustrated below)

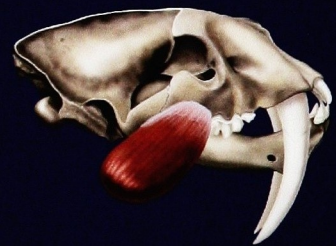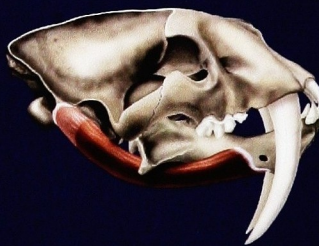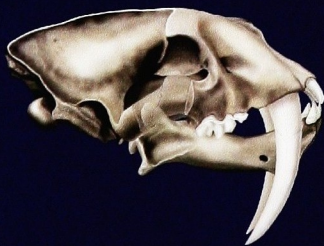The stabbing and slashing hypotheses both hinge on *Smilodon*'s jaw opening wider than 90 degrees. (illustrations to right)

Applying knowledge of tiger muscles to *Smilodon* bone leads to the conclusion that saber-tooth cats probably attacked the narrowest areas of their prey.

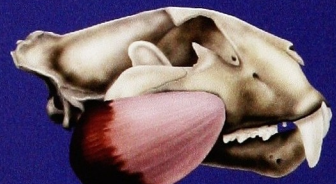
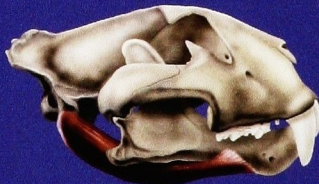
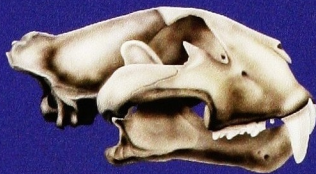## MUSCLES OF

*Smilodon fatalis* (Saber-tooth cat)



*Panthera tigris* (Modern tiger)




Digastricus - jaw opening muscle


Masseter - jaw closing muscle



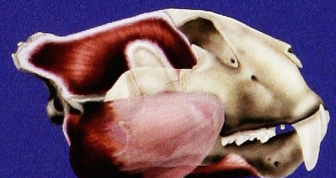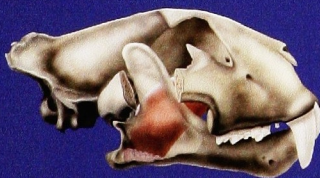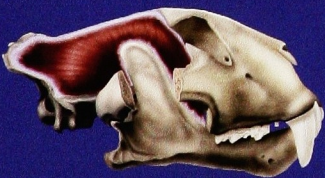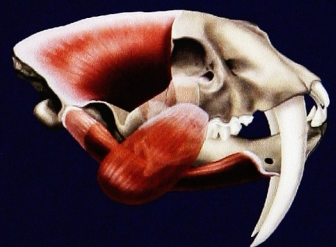
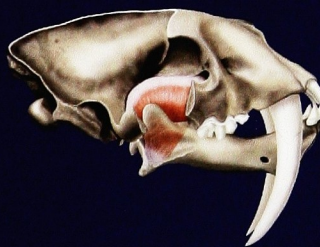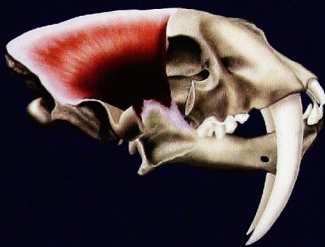
## Slashing Hypothesis



## Stabbing Hypothesis



## MASTICATION



Temporalis - jaw closing muscle

Medial Pterygoid - pulls jaw medially

All four muscles